

VARIATIONS IN CANAL ANATOMY: MANDIBULAR INCISORS

DR. SIJU JACOB

Mandibular incisors may have one or two canals. The incidence of two canals can be as high as 42%. Despite the reported high incidence of two canals in Mandibular incisors, most clinicians, when questioned, admit that the discovery of a second canal is rare in clinical practice. This article presents two documented case reports to illustrate the clinical management of Mandibular incisors with two canals.

CASE 1

A 45 year old female patient presented with severe continuous pain in the lower anterior teeth. The referring dentist informed us that all the Mandibular anterior teeth had been prepared for crowns 3 days ago and temporaries placed. The patient had developed severe pain the day after the temporaries were placed.

Clinical examination revealed discoloration, pain and tenderness on percussion in the right central and lateral incisor teeth (**Figure 1a**). A diagnosis of acute irreversible pulpitis was made and endodontic therapy was planned on both teeth.

After anesthesia and rubber dam application, an incisal access was made using burs and ultrasonics under the surgical operating microscope. Examination under magnification revealed two canals, labial and lingual in both teeth (**Figure 1b**). All canals were cleaned and shaped. In the central incisor, the canals remained independent throughout and had two separate portals of exit. In the lateral incisor, the canals merged into one.

All canals were obturated with gutta percha in warm vertical condensation technique (**Figure 1c**). The access cavity was sealed with composite resin (**Figure 1d**).

CASE 2

A 44 old male patient presented with persistent pain in the lower front teeth. The

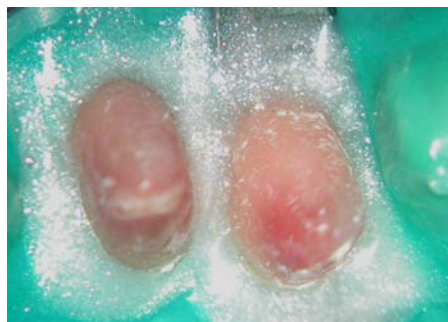

FIG 1A: Pre-operative view. Notice the discoloration

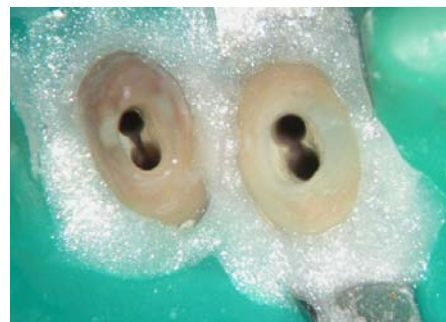

FIG 1B: Incisal access reveals two canals, labial and lingual

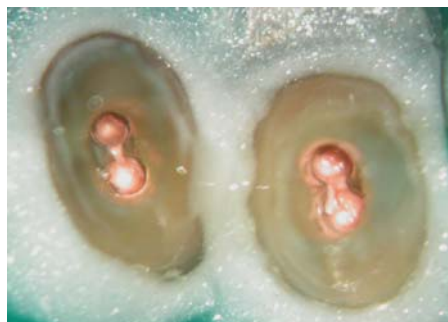

FIG 1C: Canals obturated with gutta percha in warm vertical condensation

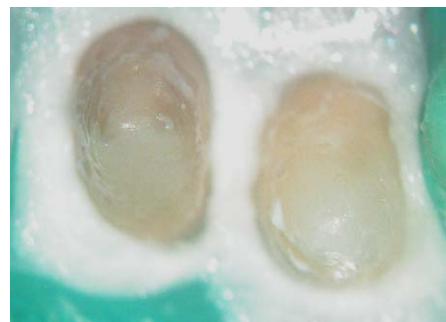

FIG 1D: Access sealed with composite resin

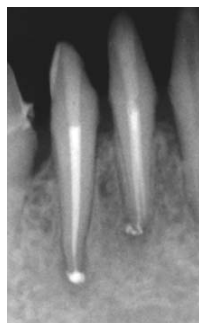

FIG 1E: Post-operative radiograph

referring dentist informed us that all four mandibular teeth had been endodontically treated two years ago and acrylic crowns placed. The patient had reported with continuous throbbing pain.

Clinical examination revealed pain and tenderness on percussion in the right cen-

tral and lateral incisor teeth. An intra-oral peri-apical radiograph revealed peri-apical radiolucencies in the previously endodontically treated mandibular central and lateral incisor. (**Figure 2a**) The canals appeared to be reasonably well obturated. A diagnosis of chronic apical periodontitis resulting from a failed root canal was made.

Treatment options were discussed with the patient and a decision was made to retreat both teeth before considering periapical surgery.

The lateral incisor was treated first. After removal of the temporary crown, an incisal access was made through the previous restoration. Refinement of the access with ultrasonics revealed the missed lingual canal. (**Figures 2b & 2c**)

Gutta percha was removed from the

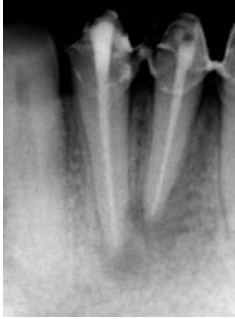

FIG 2A: Intra oral periapical radiograph shows periapical lesions in both teeth two years after endodontic therapy

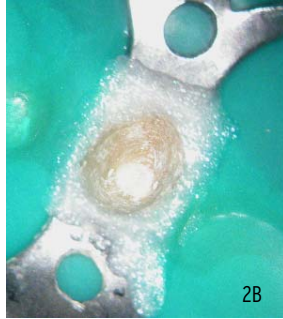


FIG 2B & 2C: Incisal access in lateral incisor reveals the filled canal as well as the missed lingual canal

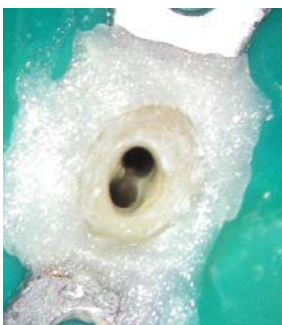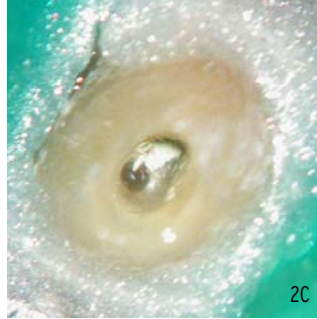


FIG 2D: Both canals cleaned and shaped

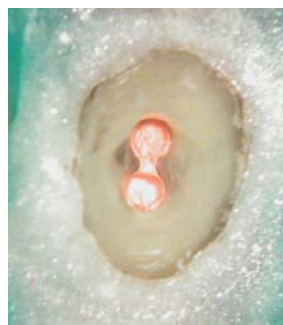

FIG 2E: Canals obturated with gutta percha in warm vertical condensation technique

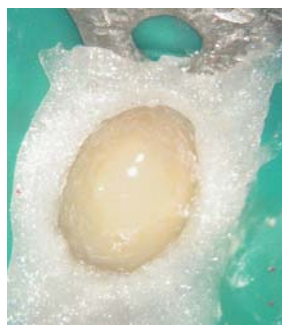


FIG 2F: Access sealed with composite resin

filled canal and both the canals were cleaned and shaped (**Figure 2d**). Calcium hydroxide was placed in both canals. After a gap of 10 days, the patient was recalled. The tooth was found to be asymptomatic. Obturation was done using gutta percha in warm vertical condensation technique (**Figure 2e**). The access cavity was sealed with dual-cured composite resin (**Figure 2f**).

The central incisor was treated in the same visit as the lateral. The clinical pattern was similar to the lateral incisor. (**Figures 3a, 3b, 3c & 3d**)

The patient was informed to report for

recalls at 6 months and 1 year to monitor the progress of the peri-apical lesion.

DISCUSSION

It is an established fact that untreated anatomy is the most common reason for failure of endodontic therapy. The Mandibular incisors are among the teeth that can have a high incidence of missed canals. The incidence of a second canal has been found to be as high as 42%. The canal that is often missed is the lingual canal. One of the reasons of the lingual canal going undetected is the conventional lingual

access which tends to direct the bur labially. A method to overcome this error is to have an incisal access.

The second case presented here illustrates the long term-problem associated with a missed canal. The presence of a lesion in spite of a "reasonably good root canal" prompts many practitioners to opt for periapical surgery in these cases. Periapical surgery without treating the missed canal will result in failure. Practitioners should be aware of the possibility of a missed canal before opting for endodontic surgery.

The surgical microscope is an invaluable tool in all aspects of endodontics. It is especially of great value in locating additional anatomy. Ultrasonics and long-shank burs help in visualization of deep anatomy.

CONCLUSION

Thorough knowledge of the incidence of extra anatomy in various teeth and developing the skill sets required to locate additional anatomy will greatly improve the predictability of endodontic therapy.

About the AUTHOR



Dr. Siju Jacob completed his B.D.S from Bangalore Institute of Dental Sciences, Bangalore and his M.D.S in Endodontics from Saveetha Dental College, Chennai. He has a practice limited to Endodontics in Bangalore. He can be contacted through his website www.rootcanalclinic.com

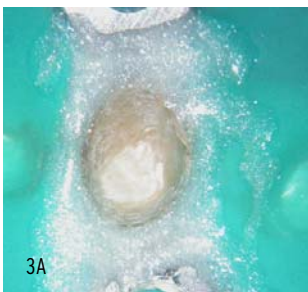


FIG 3A & 3B: Incisal access in mandibular central incisor reveals filled canal and missed lingual canal.

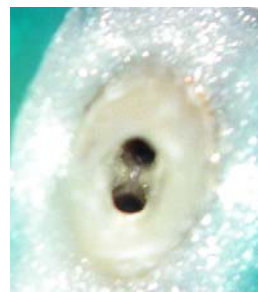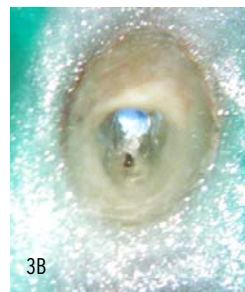


FIG 3C: Both canals cleaned and shaped

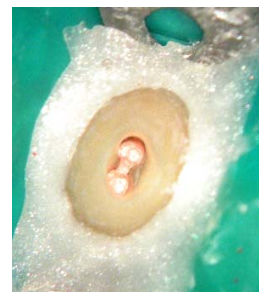

FIG 3D: Canals obturated

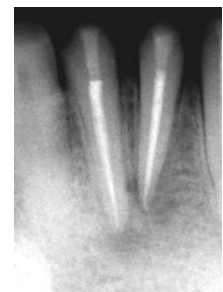

FIG 3E: Post-operative radiograph